

## The Rise of the Neophallus: A Systematic Review of Penile Prosthetic Outcomes and Complications in Gender-Affirming Surgery

Steven A. Rooker, BS,<sup>1</sup> Krishna S. Vyas, MD, PhD, MHS,<sup>2</sup> Emma C. DiFilippo, BS,<sup>1</sup> Ian T. Nolan, BM,<sup>3</sup> Shane D. Morrison, MD, MS,<sup>4</sup> and Richard A. Santucci, MD<sup>5</sup>

### ABSTRACT

**Background:** Penile prostheses are commonly used to achieve erectile rigidity after phalloplasty in trans masculine patients. Implantation poses significant challenges because of the delicate nature of the neophallus and lack of native erectile tissue. Many groups have developed novel phalloplasty and prosthesis insertion techniques, but none have proven superior.

**Aim:** To analyze and aggregate reported characteristics and outcomes of penile prosthesis implantation in the trans masculine patient.

**Methods:** A comprehensive literature search of Medline, EMBASE, and Cochrane Registry databases was conducted for studies published through February 19, 2019, with multiple search terms related to penile prosthesis use in gender-affirming surgical procedures.

**Outcomes:** Studies were included and tabulated if they reported prosthesis outcomes in patients who received a neophallus as part of a gender-affirming procedure.

**Results:** 23 journal articles met inclusion criteria from 434 references identified. All selected articles were either retrospective or case series/reports. A total of 1,056 patients underwent phalloplasty, and 792 received a penile prosthesis. Most (83.6%) of the prostheses were inflatable, whereas 16.4% were non-inflatable. The number of cylinders used for each prosthesis was 61.0% single-cylinder and 39.0% double-cylinder. The mean follow-up duration was 3.0 years. Of patients who received a prosthesis, 36.2% reported a prosthesis complication; at follow-up 60.0% of patients had their original implant present, and 83.9% reported achieving penetration.

**Clinical Implications:** Prosthesis implantation in gender-affirming operations poses significant risk of complication, but it is still a reasonable and useful method to achieve rigidity necessary for sexual intercourse.

**Strength & Limitation:** This is the first study to aggregate all reported penile prosthesis characteristics and outcomes in trans masculine patients. This study was significantly limited by inconsistent reporting of demographics, sensation, urinary health, patient satisfaction, and penetrative sex. The lack of comparative studies precluded any meaningful meta-analytical comparison.

**Conclusions:** There is a great need for a prosthesis designed to meet the specific needs of the trans masculine patient after phalloplasty. Standardized methods of reporting implant outcomes including sexual function, sensation, and patient satisfaction should be refined for future studies. This study can assist patients and surgeons about the risks and benefits of this procedure. **Rooker SA, Vyas KS, DiFilippo EC, et al. The Rise of the Neophallus: A Systematic Review of Penile Prosthetic Outcomes and Complications in Gender-Affirming Surgery. J Sex Med 2019;XX:XXX–XXX.**

Copyright © 2019, International Society for Sexual Medicine. Published by Elsevier Inc. All rights reserved.

**Key Words:** Neophallus; Phalloplasty; Penile Prosthesis; Erectile Device; Transgender; Gender Dysphoria; Female-to-Male; Outcomes; Complications

Received January 14, 2019. Accepted March 4, 2019.

<sup>1</sup>Mayo Clinic Alix School of Medicine, Rochester, MN, USA;

<sup>2</sup>Division of Plastic Surgery, Department of Surgery, Mayo Clinic, Rochester, MN, USA;

<sup>3</sup>New York University School of Medicine, New York, NY, USA;

<sup>4</sup>Division of Plastic Surgery, Department of Surgery, University of Washington School of Medicine, Seattle, WA, USA;

<sup>5</sup>Crane Surgical Services, Austin, TX, USA

Copyright © 2019, International Society for Sexual Medicine. Published by Elsevier Inc. All rights reserved.

<https://doi.org/10.1016/j.jsxm.2019.03.009>

## INTRODUCTION

Gender-affirming surgery for transgender (trans masculine, trans male, trans men, and gender diverse) men includes procedures that aim to bring the face, chest, torso, and genitals in line with a patient's gender identity. Erectile rigidity is among the most commonly reported goals of phalloplasty, alongside aesthetic acceptability, standing urination, and erogenous and tactile sensation.<sup>1–7</sup> Rigidity is not usually achieved by phalloplasty alone, because the flaps used to create the neophallus do not contain native erectile tissue. Instead, erectile prostheses (implants) are typically placed inside the neophallus. Other methods used to achieve rigidity typically involve osteocutaneous flaps or external devices.<sup>8</sup> As with phalloplasty, there are multiple techniques for prosthesis placement, and none have proven superior.<sup>8–10</sup>

Placement of penile prostheses presents specific challenges after phalloplasty for gender-affirming surgery, most notably injury to neurovascular supply, increased chance of erosion, and fixation considerations.<sup>3</sup> For most groups, prosthesis placement is typically the last step in a series of procedures and is often performed  $\geq 6$  months after the last phalloplasty or urethral operation.<sup>2–4,11–13</sup> Typically, proximally fixated Dacron or Gore-Tex (polytetrafluoroethylene; Gore Medical, Flagstaff, AZ, USA) implant sheaths are used that emulate the tunica albuginea and corpus cavernosum of cis-males; these are thought to improve fixation and prevent migration of the implant.<sup>2,3,11,12,14–18</sup> Many inflatable and non-inflatable prosthetic devices can be implanted with either 1 or 2 cylinders. The number of cylinders used on a given patient is typically dependent on anatomy and aesthetics.<sup>3,12</sup>

Available data on implant characteristics in trans masculine phalloplasty is limited. The largest study assessing this population reports on 247 transgender patients.<sup>2</sup> There remains a dearth of literature on larger retrospective studies ( $n > 30$ ) addressing implant outcomes in this patient population.<sup>2,4,12,13,19,20</sup> Most reports are found in smaller retrospective studies and case series. Although many groups have reported successful penile prosthesis implantation in the trans masculine patient, an aggregate analysis of implants use in this population has yet to be published. This study aims to aggregate reported characteristics and outcomes of penile prosthesis implantation in trans masculine patients.

## PATIENTS AND METHODS

### Literature Search

An experienced librarian conducted a comprehensive literature search of Medline, EMBASE, and Cochrane Registry for studies published through February 19, 2019, for the use of penile prostheses in gender-affirming procedures. Medical Subject Heading terms “transgender persons” OR “transsexualism” OR “sex reassignment procedure” OR “penile prosthesis” OR “gender affirmation” OR “gender confirmation” were queried,

along with similar derivations of each. Titles, abstracts, and full text articles were screened by 2 independent reviewers (S.R. and E.D.). Any disagreements were resolved by consulting a third author (K.V.). Full text articles were then analyzed independently by 2 reviewers (S.R. and E.D.). Additional studies were identified within the bibliography of screened references. A rigorous review of identified references was performed in accordance with the Preferred Reporting Items for Systematic Reviews and Meta-Analysis checklist.<sup>21</sup>

### Variables of Interest

Articles were included if they reported penile prosthesis data for patients who were  $\geq 18$  years old and previously received a neophallus as part of a gender-affirming surgery. It should be noted that, throughout the article, the use of the term “transgender” is meant to incorporate the gender-diverse population seeking genital gender-affirming surgery. Articles were excluded if there was no primary research data or limited penile implant data, the articles were not related to gender-affirming surgery, patients were  $< 18$  years old, and follow-up was  $< 6$  months. Conference abstracts and articles not available in English were also excluded. If articles reported on the same patient population, then only the most comprehensive with the longest follow-up was included. Data, including demographics, comorbidities, type of implant, type of neophallus, nerves coapted during phalloplasty, time to implant, sensation outcomes, sexual function, patient-reported outcomes, and complications, were collected.

### Statistical Analysis

Results were tabulated and descriptive statistics (mean, median, range, and proportions) were reported across studies. Calculations were performed in Microsoft Excel (Redmond, WA, USA). Implant complications were reported or extrapolated as total number of patients with complications. Meta-analytic comparisons were not feasible due to limitations of the available literature.

## RESULTS

A total of 434 references were identified during the initial database search. After duplicates were removed, 415 total references were identified. From this list, 6 references not available in English were excluded. A total of 409 references were screened; 359 references were excluded for not meeting study criteria. During the initial screen, 2 additional articles were identified through other sources. A total of 52 full-text articles were reviewed in detail, of which 23 met inclusion criteria (Figure 1). Of the 23 articles that met inclusion criteria, 1 article reported using a transgender-specific prosthesis and was excluded from the tabulated statistics.<sup>22</sup> The results from 22 articles that used cis-male prostheses were tabulated.

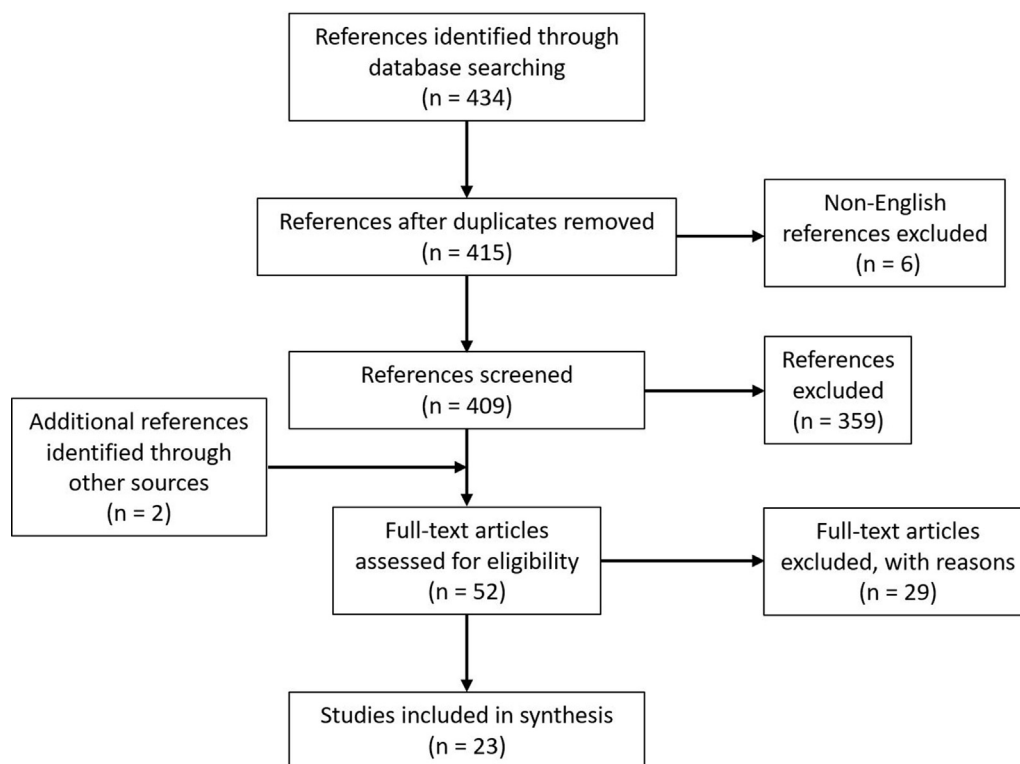


Figure 1. Schematic of literature search.

### Demographics and Operative Intervals

Of the 22 articles tabulated, 16 reported exclusively on trans masculine patients. Within the 22 articles, 96.6% (N = 1,056) of the patients were trans masculine. 4 articles reported aggregated data that included 30 non-transgender patients<sup>4,6,11,23</sup>; 2 articles reported non-aggregated data for 6 trans masculine and 6 non-transgender patients.<sup>18,24</sup> Of these 22 articles, 792 patients received a penile implant. Of the 792 who received a penile implant, 762 (96.2%) were trans masculine patients. The remaining 30 non-transgender patients who received an implant were reported within aggregated data.

A total of 7 articles reported a mean age at implantation of 36.7 years accounting for 422 patients.<sup>2,11,12,16,18,23,25</sup> 8 articles reported a mean interval to implantation after phalloplasty of 2.4 years for 177 patients.<sup>11,12,16,17,23,26–28</sup> 1 article did not report a mean but reported a median interval to implant of 1.6 years for 69 patients.<sup>4</sup>

### Phalloplasty

The specific type of phalloplasty was reported for 1,032 patients from all 22 articles (Table 1). The most common types of phalloplasty were radial forearm free flap (RFFF) (53.1%, n = 548), suprapubic/infraumbilical (19.4%, n = 200), perineal/groin flap (12.8%, n = 132), and latissimus dorsi free flap (12.6%, n = 130). The remaining 2.1% (n = 22) included anterolateral thigh, tensor fasciae latae, lateral arm, rectus abdominis, and gracilis flaps. The type of phalloplasty for 3 patients was not mentioned.

### Implant

The type of implant was reported for 649 patients from 20 articles (Table 2). A total of 824 implants were used among these patients. Most implants were inflatable (83.6%, n = 689); the remainder were non-inflatable (16.4%, n = 135). 2 articles not included in Table 2 reported using implants but did not describe the exact amount of inflatable and non-inflatable devices.<sup>13,19</sup> The number of cylinders used per implant was reported for 515 surgeries within 9 articles (Table 3).<sup>2,11,12,15,17,18,23,24,28</sup> Most operations used a single-cylinder implant (61.0%, n = 314); double cylinder implants were used in the remaining operations (39.0%, n = 201).

### Follow-up, Outcomes, and Complications

Follow-up period was reported by 13 articles. 12 articles reported a mean follow-up duration of 3.0 years (N = 580)<sup>2,12,14,15,17,19,24–26,28–30</sup> (Table 4). 1 article did not report a mean but reported a median follow-up duration of 4 years (N = 69).<sup>4</sup> At latest follow-up, successful penetration was reported by 83.9% of patients (N = 230) from 8 articles.<sup>2,17,19,24,25,29–31</sup> Additionally, 15 studies reported that 305 (60.0%) original implants were still in place at follow-up of 508 total patients (Table 4).<sup>2,4,12,14–19,24–29</sup> Of these 15 studies, 10 reported a mean follow-up duration of 2.6 years (N = 433 patients); 1 study reported a median follow-up duration of 4 years (N = 69 patients).<sup>2,12,14,15,17,19,24–26,28,29</sup> 3 studies reported that the original implant was in place at follow-up in 4 of 6 patients but did not report a follow-up duration.<sup>16,18,27</sup>

**Table 1.** Type of phalloplasty (N = 1,032)

Type of phalloplasty	Patients, % (n)
Radial forearm free flap	53.1 (548)
Suprapubic/infraumbilical	19.4 (200)
Perineal/groin flap	12.8 (132)
Latissimus dorsi free flap	12.6 (130)
Other	2.1 (22)

The source of flap used to make a phallus in each of the 1032 patients from 22 articles.

The total complication rate was calculated by tabulating any complication that required or requires an additional surgical intervention (Table 5). This can include interventions such as implant replacement, explantation, revision, or flap loss after implant insertion. The total complication rate was determined to be 36.2% (n = 287) of 792 patients who received an implant from all 22 articles. The total complication rate for inflatable and non-inflatable prostheses is reported in Table 5. 5 articles reported prosthesis complications but did not stratify the complications against inflatable and non-inflatable types and, thus, were excluded from this calculation.<sup>6,11,13,19,32</sup> The total inflatable complication rate was 45.2% (n = 217) of 480 patients from 12 studies reporting this outcome.<sup>2,4,12,15–18,23,24,27,29,31</sup> The total non-inflatable complication rate was 41.5% (n = 26) of 65 patients from 9 studies reporting this outcome.<sup>4,14,18,20,25,26,28,29,31</sup>

The specific type of complication (including aggregated inflatable and non-inflatable data) was reported in 20 articles, accounting for 707 patients. 2 articles did not report the specific type of complication.<sup>19,20</sup> Of these 707 patients, 12.0% (n = 85) reported a mechanical failure, dysfunction, or leak. An additional 8.6% (n = 61) reported infection of device; 6.8% (n = 48) reported dissatisfaction, which ultimately led to a new surgery. Inadequate fixation, migration, or malpositioning was reported by 5.2% (n = 37), and 3.4% (n = 24) reported erosion. Other specific types of complications were reported by 1.0% (n = 7) of patients. These complications included capsular fibrosis (n = 3), malleable fracture (n = 1), and venous thrombosis requiring removal of the implant (n = 1); the details of 2 patients were not reported. No study reported flap loss after insertion of a prosthesis.

The total number of patients (N = 1,056), trans masculine patients (N = 1,020), and patients with implants (N = 792) is

**Table 2.** Implant type (N = 824)

Type of implant	Implants, % (n)
Inflatable	83.6 (689)
Non-inflatable (semirigid malleable and non-malleable rod)	16.4 (135)

A total of 824 implants were either inflatable or non-inflatable for each of the 649 patients from 20 articles that reported this outcome.

**Table 3.** Number of cylinders, (N = 515)

Number of cylinders	Percent of patients, % (n)
Single-cylinder	61.0 (314)
Double-cylinder	39.0 (201)

The multiplicity of erectile prostheses in each phallus was either single-cylinder or double-cylinder, in a total of 515 implants from 9 articles reporting this outcome.

shown with the corresponding article in Table 6. Additionally, the type of neophallus (flap), nerves coapted during phalloplasty, type of implant (inflatable vs non-inflatable), implant model, type of implant graft, total patients with implant complications, and complication rates are listed. In Table 6, non-aggregated data from 1 article that used a phalloplasty (transgender)-specific prosthesis, ZSI 475 FtM (Zephyr Surgical Implants, Geneva, Switzerland), are shown.<sup>22</sup>

## DISCUSSION

This study aimed to aggregate all reported penile implant characteristics and outcomes in trans masculine patients undergoing phalloplasty for gender affirmation. Placement of erectile prostheses may increase the already considerable complication rates associated with phalloplasty in trans masculine patients, yet aggregate data on penile implants in gender affirming surgery has not been compiled.<sup>9,10,33–37</sup> This study analyzed 23 articles reporting trans masculine penile implant characteristics and outcomes spanning from 1993–2019. Of these, data from 22 articles using cis-male prostheses are tabulated in the results section. Few articles reported on large retrospective patient cohorts.<sup>2,4,12</sup> The remaining articles mostly reported phalloplasty outcomes with scant mention of implant data.

An ideal phalloplasty technique still has not been elucidated; overwhelmingly, groups have favored the RFFF phalloplasty (53.1%), but other phalloplasty techniques are still prevalent (Table 1). Regardless of the phalloplasty technique used, most authors agree it is best to allow the neophallus to heal and achieve tactile sensation before insertion of a penile implant; adequate

**Table 4.** Long-term outcomes of phalloplasty with prosthesis placement

Outcome	Patients, % (n)
Mean follow-up duration, y (N = 580)	3.0
Median follow-up duration, y (N = 69)	4.0
Achieving penetration with neophallus and prosthesis (N = 230)	83.9 (193)
Original prosthesis present (N = 508)	60.0 (305)

Including mean (580 patients from 12 articles) and median (69 patients from 1 article) follow-up duration, percent of patients achieving penetrative intercourse (230 patients from 8 articles reporting this outcome), and percent of patients with their original prosthesis present at 2.6 years average follow-up (508 patients from 15 articles).

**Table 5.** Complications after implant placement

	Patients, % (n)
Total complications	
Total complication rate	36.2 (287)
Total inflatable complication rate	45.2 (217)
Total non-inflatable complication rate	41.5 (27)
Specific complications	
Mechanical failure, dysfunction, or leak	12.0 (85)
Infection of device	8.6 (61)
Patient dissatisfaction	6.8 (48)
Inadequate fixation, migration, or malpositioning	5.2 (37)
Erosion	3.4 (24)
Other	1.0 (7)

The total complication rate accounts for any complication which required or requires additional surgical intervention after implant insertion of 792 patients from 22 articles at latest follow-up. The total inflatable and non-inflatable complication rates report complications that were stratified by implant type. The total inflatable complication rate accounts for 480 patients from 12 articles. The total non-inflatable complication rate accounts for 65 patients from 9 articles. The specific type of complication was reported for 707 patients from 20 articles. The most consistently reported complications were grouped in categories: mechanical failure, dysfunction, or leak; infection of device; patient dissatisfaction; inadequate fixation, migration, malpositioning; erosion; and other.

restoration of sensation typically is achieved around 6 months after the last phalloplasty operation, but improvements in sensation can be seen much later<sup>2-4,11-13,38</sup> (Figure 2 demonstrates a successful implantation). Before implant insertion, it is important to identify the unique anatomy of a patient's neophallus. For example, flaps such as the RFFF involve delicate microvascular coaptation from flap to recipient vessels and nerves.<sup>9</sup> Additionally, these neophalluses may have concomitant neourethras, the location of which must be considered when sizing and placing a prosthesis.<sup>9,39</sup> When choosing an approach for prosthesis insertion (eg, suprapubic, infrapubic, penoscrotal, perineal), it is important to identify and consider the flap specific anatomy.<sup>9,39</sup> In this study, all authors report prosthesis implantation as a separate procedure after phalloplasty.

It is well observed that sensation outcomes can vary depending on the phalloplasty type (ie, pedicled vs free flaps) and nerves coapted at phalloplasty when applicable.<sup>9,38</sup> Our group originally hypothesized that increased sensation could improve the outcomes of penile prostheses in this population. In this study, nerves coapted during phalloplasty were often reported (Table 6), but sensation outcomes both before and after implantation, including tactile/cutaneous/erogenous sensation, were not reported consistently and thus were not a useful variable for comparison.

The most commonly used implant models were initially intended to treat erectile dysfunction in non-transgender male patients. These implants are designed with cis-male anatomy in mind and thus do not address the specific needs of the trans

masculine patient. 1 obvious difference when placing prostheses in phalloplasty patients is the lack of crus penis or corpora cavernosa generally used for implant fixation, and its absence is thought to increase the chance of implant migration and malpositioning. This difference is addressed by a variety of techniques: surrounding the implant in a proximally fixated vascular or mesh graft (most often Dacron or Gore-Tex), and proximal bone fixation with standard sutures, titanium sutures (Fiberwire; Arthrex, Naples, FL, USA) or bone anchors. Common positioning and fixation complications can be seen in Figures 3 and 4. 14 of the 22 articles reported using an implant graft to improve fixation and prevent distal erosion (Table 6). Hoebeke and colleagues<sup>12</sup> reported abandoning Dacron vascular grafts for inflatable prostheses in 2006 because of high rates of implant dysfunction; both Falcone et al<sup>2</sup> and Neuville et al<sup>4</sup> make note of grafts leading to increased risk of mechanical dysfunction, perhaps due to increased wear on the implant, but still favor using them.

There did appear to be a relative increase in the proportion of inflatable prostheses used since 1993, and overwhelmingly the most recent studies favor inflatable prostheses (Table 6). Additionally, many articles made mention that the lack of native erectile tissue, including the corpus cavernosum and tunica albuginea, may predispose phalloplasty patients to erosion. In this study, 83.6% of implants were inflatable vs 16.4% non-inflatable. Although conjecture, inflatable implants seem to decrease the likelihood of erosion compared with non-inflatable implants because of the ability to soften the implant when non-erect.<sup>11</sup> Few groups have reported using a significant number of non-inflatable implants in their phalloplasty operations in the last 2 decades. The groups from Zuckerman et al<sup>11</sup> and Bettocchi et al<sup>31</sup> are the 2 most notable groups who have. In the study by Zuckerman et al,<sup>11</sup> no inflatable implants eroded, whereas 2 non-inflatable implants eroded; and, in the study by Bettocchi et al,<sup>31</sup> 75% of non-inflatable implants were lost due to erosion, although no inflatable complications were reported.

The number of cylinders used per implant is often reported to be an intraoperative decision based on neophallus size (length and girth), surrounding structures (eg, neourethra), aesthetics of the neophallus, as well as surgeon's preference.<sup>12</sup> The numbers of cylinders used per implant in this study was 61.0% of patients receiving a single-cylinder implant and 39.0% double-cylinder (Table 3). The status of the literature made tabulating the type of implant (inflatable and non-inflatable) vs the number of cylinders infeasible. Although many groups report the number of cylinders implanted, only Hoebeke et al<sup>12</sup> attempted to stratify the 185 implants used based on cylinders (127 single-cylinder; 58 double-cylinder). No significant differences in infection, erosion, mechanical function, or malpositioning were reported. Although conjecture, Hoebeke et al<sup>12</sup> did report that single-cylinder implants led to a more aesthetically appealing outcome. This is likely due to the absence of native erectile tissue and fascia within the neophallus, which is useful for prosthesis

Table 6. Identified articles

Author(s), year	Total patients*	Total trans masculine patients	Total patients with implant†	Type of flap (n)‡	Nerves connected during phalloplasty	Implant type (n)	Implant model (n)§	Type of implant graft	Total patients with implant complication	Implant complication rate (%)¶
Neuville et al <sup>22,#</sup>	20	20	20	RFFF (15) Suprapubic (4) Groin (1)	NR	Inflatable (21)	ZSI 475 FtM (21)	NR	4	20.0
Djordjevic et al <sup>32</sup>	129	129	61	Latissimus dorsi flap (129)	Thoracodorsal to ilioinguinal	Inflatable (22) Non-inflatable (39)	AMS 700 LGX (22) Coloplast Genesis (39)	NR	4	6.6
Falcone et al <sup>2</sup>	247	247	247	RFFF (157) Infraumbilical pubic flap (90)	NR	Inflatable (328)	AMS 700 CX (226) AMS 700 CXM/R (31) Coloplast Titan (58) AMS Ambicor (13)	Dacron (silver-coated after 2009)	107	43.3
Cohen et al <sup>23</sup>	10	8	10	RFFF (10)	NR	Inflatable (17)	AMS 700 CX (NR) AMS 700 LGX (NR)	Gore-Tex	7	70.0
van der Sluisset al <sup>26</sup>	19	19	1	ALT (1)	Lateral femoral cutaneous to dorsal clitoral	Non-inflatable (1)	Coloplast Genesis (1)	NR	0	0
Djordjevic et al <sup>29</sup>	7	7	4	Latissimus dorsi flap (7)	Thoracodorsal to ilioinguinal	Inflatable (1) Non-inflatable (3)	NR	NR	0	0
Neuville et al <sup>4</sup>	69	62	69	RFFF (40) Suprapubic (23) Groin (3) Other (3)	NR	Inflatable (94) Non-inflatable (1)	AMS 700 CX (1) AMS 700 CXM/R (3) AMS Ambicor (90) AMS 600-650 (1)	HEMASHIELD GOLD (Maquet Getinge Group, Rastatt, DE)	26	37.7
Zuckerman et al <sup>11</sup>	31	15	31	RFFF (30) Groin (1)	Cutaneous to clitoral	Inflatable (10) Non-inflatable (21)	AMS 700 CX (NR) AMS 700 CXR (NR) Coloplast Titan (NR) DuraPhase AMS Spectra (NR)	Gore-Tex	7	22.6
Hoebeke et al <sup>12</sup>	129	129	129	RFFF (129)	Antebrachial to ilioinguinal and dorsal clitoral	Inflatable (185)	AMS 700 CX (34) AMS 700 CX/CXM (69) AMS Ambicor (59) AMS Dynaflex (15) Coloplast/Mentor (8)	Dacron (prior to 2006 only)	72**	**55.8
Large et al <sup>15</sup>	2	2	2	RFFF (2)	NR	Inflatable (3)	AMS 700 (3)	NR	0	0

(continued)

Table 6. Continued

Author(s), year	Total patients*	Total trans masculine patients	Total patients with implant <sup>†</sup>	Type of flap (n) <sup>‡</sup>	Nerves connected during phalloplasty	Implant type (n)	Implant model (n) <sup>§</sup>	Type of implant graft	Total patients with implant complication <sup>  </sup>	Implant complication rate (%) <sup>  </sup>
Solinc et al <sup>14</sup>	2	2	2	RFFF (2)	Lateral antebrachial to dorsal clitoral	Non-inflatable (2)	Silicone rod (2)	Dacron	0	0
Rubino et al <sup>25</sup>	1	1	1	ALT (1)	lateral cutaneous femoral to right dorsal clitoral	Non-inflatable (1)	Silicone rod (1)	Fascia lata strip	0	0
Leriche et al <sup>19</sup>	56	56	38	RFFF (56)	Musculocutaneous to dorsal clitoral	NR	AMS Ambicor (NR) AMS 600 (NR) AMS 700S (NS)	NR	11	28.9
Krueger et al <sup>13</sup>	105	105	105	RFFF (105)	NR	NR	AMS Malleable 650 (NR) AMS Dynaflex (NR) AMS 700 CXM (NR)	NR	17	16.2
Bettocchi et al <sup>31</sup>	85	85	17	Suprapubic (85)	NR	Inflatable (9) Non-inflatable (8)	AMS Dynaflex (9) Silicone rod (8)	Dacron	6	35.3
Santanelli and Scuderi <sup>27</sup>	5	5	2	Sensate tensor fasciae latae island flap (5)	NR	Inflatable (2)	AMS Dynaflex (2)	Gore-Tex	0	0
Tan <sup>16</sup>	1	1	1	Anterior abdominal subcutaneous fat (1)	NR	Inflatable (1)	AMS 700 CX (1)	Dacron	0	0
Zielinski <sup>20</sup>	127	127	47	Lateral groin (127)	NR	Non-inflatable (47)	Silicone rod (41) Knitted polyester-polypropylene (6)	NR	19	40.4
Khouri et al <sup>24</sup>	4	3	3	Lateral arm (3)	Brachial and antebrachial to erogenous branches of internal pudendal	Inflatable (3)	NR	NR	0	0
Hage <sup>17</sup>	5	5	5	RFFF (5)	Cutaneous n. to dorsal clitoral	Inflatable (7)	AMS Dynaflex (7)	Dacron	4	80.0
Alter et al <sup>6</sup>	13	8	13	RFFF (10) Gracilis (1) Perineal (1) Other (1)	Flap to pudendal	Inflatable (4) Non-inflatable (10)	AMS 700 CX (2) DuraPhase (10) Uniflate 1000 (2)	Gore-Tex	4	30.8

(continued)

Table 6. Continued

Author(s), year	Total patients*	Total trans masculine patients*	Total patients with implant <sup>†</sup>	Type of flap (n) <sup>‡</sup>	Nerves connected during phalloplasty	Implant type (n)	Implant model (n) <sup>§</sup>	Type of implant graft	Total patients with implant complication <sup>  </sup>	Implant complication rate (%) <sup>  </sup>
Jordan et al <sup>18</sup>	8	3	3	RFFF (2) Perineal (1)	NR	Inflatable (3) Non-inflatable (1)	Duraphase (1) Uniflate 1000 (3)	Core-Tex	2	66.7
Fisch et al <sup>28</sup>	1	1	1	Latissimus dorsi (1)	Flap to pudendal	Non-inflatable (1)	Silicone rod (1)	Polypropylene hose	1	100
Total	1,056	1,020	792	1,032		Inflatable (689) Non-inflatable (135)			287	

ALT = anterolateral thigh; NR = not reported; RFFF = radial forearm free flap.

\*Total patients—can include non-transgender patients.

<sup>†</sup>Total patients with implant—only trans masculine patients reported, if possible.

<sup>‡</sup>Type of flap (n)—non-transgender patients removed from count, if possible.

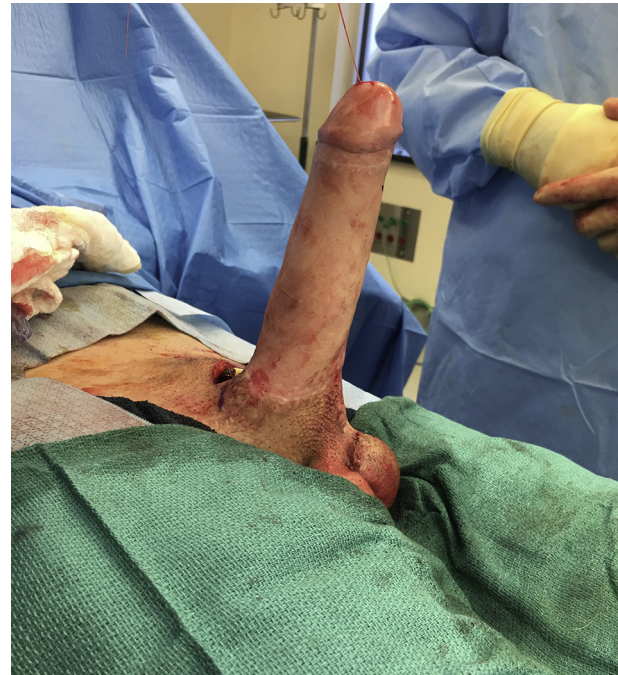<sup>§</sup>Implant model (n)—if possible, only implant models for trans masculine patients was reported; number used for each model provided, if possible.

<sup>||</sup>Total patients with implant complications—if possible, only complications involving trans masculine patients reported.

<sup>||</sup>Implant complication rate (%)—complication that required or requires an additional surgical intervention, defined as number of patient complications/total patients.

<sup>#</sup>Article using transgender-specific prosthesis and thus not reported in tabulated results.

\*\*Total adjusted to report number of patients with complications; rate adjusted to include malpositioning as a complication (originally reported as 41.1%).



**Figure 2.** Satisfactory placement in trans masculine patient. This demonstrates intraoperative placement of a single cylinder Coloplast Titan via a suprapubic approach into a radial forearm free flap neophallus. The pump is placed into the left hemiscrotum, and the right hemiscrotum has a Coloplast Torosa implant. Figure 2 is available in color online at [www.jsm.jsexmed.org](http://www.jsm.jsexmed.org).

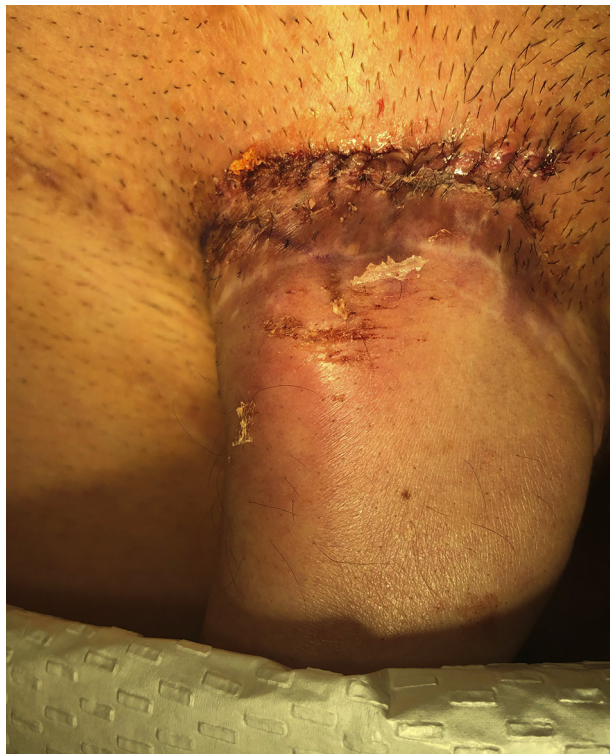fixation (eg, corpus cavernosum, tunica albuginea, deep fascia, etc). This absence could conceivably lead to a worsened cosmetic defect if multiple cylinders are implanted.

Surprisingly, only 8 studies (N = 230 patients) reported whether implantation of a penile prosthesis led to successful penetrative sexual intercourse (Table 4). However, of those who did report this finding, on average, 83.9% of patients were able to achieve penetration. No study noted any difference in penetration rates between specific implant types or number of cylinders. 1 article noted that some patients were not engaging in penetrative sexual intercourse due to lack of a partner.<sup>2</sup> Consistent reporting of this variable in future studies would be useful to determine the effectiveness of penile prostheses in this patient population.

2 groups mentioned using a non-validated questionnaire for transgender patients to determine sexual function after phalloplasty and implant insertion.<sup>2,19</sup> 1 group reported using a questionnaire validated for hypospadias patients.<sup>32</sup> Further information on patient-reported outcomes in this realm would be useful.<sup>40,41</sup>

It has been known that phalloplasty and penile implant insertion is often plagued by postoperative complications. The aggregated complication rate calculated in this study was 36.2% (Table 5). This is slightly lower than the reported complication rates in the 3 largest retrospective studies on this topic, likely due to reporting bias in the smaller studies.<sup>2,4,12</sup> The total inflatable

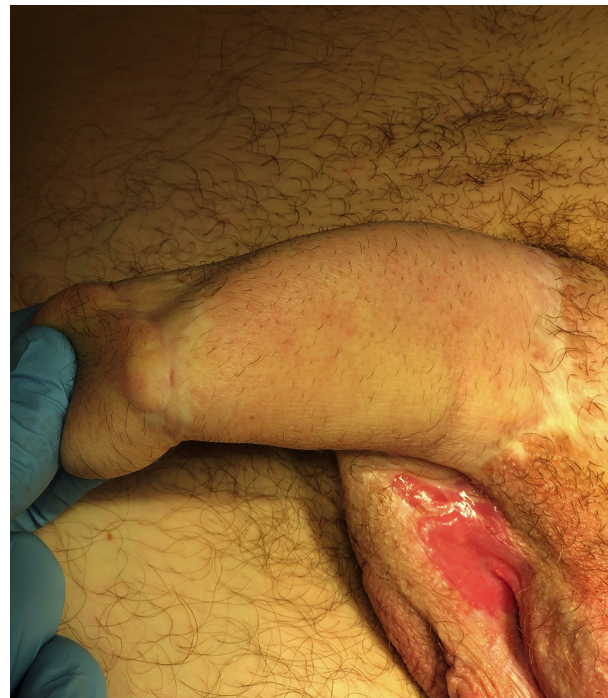



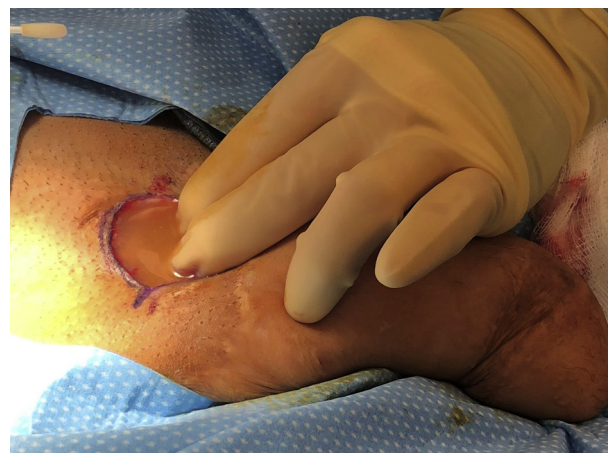**Figure 3.** Proximal malposition. 9 days after inflatable prosthesis placement, patient presented with concerning dorsal penile bulge and mild erythema roughly 1 cm distal to the incision site. This form of minor malposition occurs when the prosthesis partially lifts out of the phallus when inflated. Although unsightly, this problem is easily remedied by applying firm pressure with the palm on the lower pubis just superior to the phallus. This defect eventually healed, no longer requiring this maneuver, and the patient reported a satisfactory outcome at follow-up. Figure 3 is available in color online at [www.jsm.jsexmed.org](http://www.jsm.jsexmed.org).

and non-inflatable complication rates were 45.2% and 41.5%, respectively (Table 5). These rates were increased due to the exclusion of 5 articles that used both inflatable and non-inflatable prostheses but did not stratify complications by prosthesis type.<sup>6,11,13,19,32</sup> However, these complication rates are in line with the complication rates published in the larger retrospective studies.<sup>2,4,12</sup> Due to the status of the literature, it was infeasible to compare complication rates and time to implant after phalloplasty. Surprisingly, no study reported any patients suffering from flap loss after prosthesis insertion. This is likely due to most surgeons opting for a staged approach, waiting until the neophallus has healed and regained sensation before prosthesis insertion. In Figure 5, an example of a postoperative infection requiring implant removal is seen.

At follow-up, 15 articles reported that 60.0% (n = 305) of the original implants were still present (Table 4). However, the mean and median follow-up duration for the entire study was reported to be only 3.0 and 4 years, respectively (N = 512 and N = 69) (Table 4). The 3 most robust retrospective studies were able to calculate implant lifespan using survival plots. Hoebek et al<sup>12</sup> calculated a 60% implant failure rate after 4.7 years, Neville



**Figure 4.** Dorsal malposition. At follow-up, patient presented with contracture of the capsule around the semi-rigid prosthesis. This contracture caused the prosthesis to deviate from its ideal position in the dorsal base of the phallus. Although this complication represents a malpositioning, the patient was satisfied with the function and cosmesis of the implant and required no further intervention. Figure 4 is available in color online at [www.jsm.jsexmed.org](http://www.jsm.jsexmed.org).



**Figure 5.** Implant infection. Patient presented after surgery with pain and suprapubic swelling after placement of dual cylinder semi-rigid implants, surrounded with Gore-Tex arterial grafts. During an exploratory operation, 200 mL of milky yellow fluid was discovered around the base of both prostheses. Intraoperative cultures were negative, but the patient received intravenous vancomycin and gentamycin before surgery. Patient tolerated removal of the prosthetic and will be reimplemented after a 6-month waiting period. Figure 5 is available in color online at [www.jsm.jsexmed.org](http://www.jsm.jsexmed.org).

et al<sup>4</sup> reported a median implant life expectancy of 4.2 years, and Falcone et al<sup>2</sup> calculated a 5-year implant survival rate of 78% .

Recently, Neville and colleagues<sup>22</sup> published the first outcomes data using the ZSI 475 FtM, a phalloplasty-specific inflatable prosthesis that has been available in Europe since March 2016. The data from this article were not included in the aggregate analysis because it was the only study to use a prosthesis designed for phalloplasty and thus cannot be compared with cis-male prostheses outcomes. This prosthesis offers a larger area for pubic bone fixation, realistically-shaped hard glans at the distal end of the prosthesis, and a testicle-shaped pump.<sup>22</sup> These design features address the unique anatomy of the phalloplasty patient.<sup>22</sup> The authors hypothesize that this new design can potentially improve the lifespan of the prosthesis, improve penetration with realistically-shaped hard glans, and improve aesthetic appeal.<sup>22</sup>

The published outcomes of the ZSI 475 FtM prosthesis reports on data from 20 patients.<sup>22</sup> An overall implant revision rate was determined to be 19.0% (n = 4), of 21 total implants (4 total patient complications).<sup>22</sup> These complications included 2 mechanical failures, 1 infection, and 1 malpositioning.<sup>22</sup> However, the mean follow-up period was only 8.9 months.<sup>22</sup> The authors report 14 patients answered 3 validated questionnaires (The International Index of Erectile Function-5, Erectile Dysfunction Inventory of Treatment Satisfaction, and The Self Esteem and Relationship questionnaire), as well as 1 non-validated questionnaire specifically analyzing the prosthesis.<sup>22</sup> Overwhelmingly, the patients were satisfied with their prosthesis (92.8% of patients were “satisfied” or “very satisfied”), and 85.7% reported penetrative sexual intercourse.<sup>22</sup> Overall, the ZSI 475 FtM seems to be promising, but certainly a larger sample and longer follow-up is needed.

This study was significantly limited by the quality of the literature available. Inconsistent reporting of demographic data, outcomes such as tactile and erogenous sensation, urinary health, patient satisfaction, and ability to engage in penetrative sex, limited our analysis to mainly descriptive statistical analysis. It should be noted that few studies reported all variables collected within the results of this review (eg, successful penetrative sex reported by 8 studies). The lack of comparative studies reporting separate outcomes for differing techniques for phalloplasty or erectile prosthesis placement precluded any meaningful meta-analytical comparisons. The lack of standardized patient-reported outcomes measures for gender-affirming surgery further limited any comparisons of patient-reported outcomes, such as sexual performance or aesthetic satisfaction. An effort was made to include studies that reported only on implant outcomes for trans masculine patients; however, the status of the literature made that difficult, and, thus, some articles with non-transgender patients were included. Further research is needed for the development of patient-reported outcomes in gender-affirming care, long-term complications after implant insertion, and on training needed for these complex procedures.<sup>40,42-45</sup>

## CONCLUSION

Although penile prosthesis implantation in the trans masculine patient poses significant risk of complications, including, but not limited to, mechanical failure, infection, and malpositioning, it is still a reasonable and useful method to achieve rigidity necessary for penetrative sexual intercourse. Cis-male penile prostheses have been the standard for phalloplasty operations since the procedure's conception, but an implant designed to meet the specific needs of trans masculine patients may improve outcomes. Standardized methods of reporting implant outcomes, including sexual function, sensation, and patient satisfaction, should be refined for future studies. This series can assist patients and surgeons to evaluate the reported risks and benefits of this procedure.

## ACKNOWLEDGMENTS

The authors would like to acknowledge and thank the Mayo Clinic librarian, Mr. Larry Prokop, for his assistance with the literature search.

**Corresponding Author:** Steven A. Rooker, Mayo Clinic Alix School of Medicine, 200 1<sup>st</sup> Street SW, Rochester, MN 55902, USA. Tel: 303-947-8694; Fax: 507-538-1987; E-mail: [rooker.steven@mayo.edu](mailto:rooker.steven@mayo.edu)

*Conflict of Interest:* The authors report no conflicts of interest.

*Funding:* None.

## STATEMENT OF AUTHORSHIP

### Category 1

#### (a) Conception and Design

Krishna S. Vyas; Shane D. Morrison; Richard A. Santucci

#### (b) Acquisition of Data

Steven A. Rooker; Krishna S. Vyas; Emma C. DiFilippo; Ian T. Nolan; Shane D. Morrison

#### (c) Analysis and Interpretation of Data

Steven A. Rooker; Emma C. DiFilippo; Ian T. Nolan; Shane D. Morrison

### Category 2

#### (a) Drafting the Article

Steven A. Rooker; Emma C. DiFilippo; Ian T. Nolan; Shane D. Morrison

#### (b) Revising It for Intellectual Content

Steven A. Rooker; Krishna S. Vyas; Ian T. Nolan; Shane D. Morrison; Richard A. Santucci

### Category 3

#### (a) Final Approval of the Completed Article

Steven A. Rooker; Krishna S. Vyas; Emma C. DiFilippo; Ian T. Nolan; Shane D. Morrison; Richard A. Santucci

## REFERENCES

1. Nolan I, Crowe CS, Massenburg BB, et al. Cultural considerations regarding glansplasty. *Plast Reconstr Surg* 2018;142:427e.

2. Falcone M, Garaffa G, Gillo A, et al. Outcomes of inflatable penile prosthesis insertion in 247 patients completing female to male gender reassignment surgery. *BJU Int* 2018; **121**:139-144.
3. Dy GW, Weinberg A, Zhao LC. Prosthetic considerations in neophallic reconstruction. *Curr Sex Health Rep* 2017; **9**:207-213.
4. Neuville P, Morel-Journal N, Maucourt-Boulch D, et al. Surgical outcomes of erectile implants after phalloplasty: Retrospective analysis of 95 procedures. *J Sex Med* 2016; **13**:1758-1764.
5. Monstrey S, Hoebeke P, Dhont M, et al. Surgical therapy in transsexual patients: A multi-disciplinary approach. *Acta Chir Belg* 2001; **101**:200-209.
6. Alter GJ, Gilbert DA, Schlossberg SM, et al. Prosthetic implantation after phallic construction. *Microsurgery* 1995; **16**:322-324.
7. Jacobsson J, Andreasson M, Kolby L, et al. Patients' priorities regarding female-to-male gender affirmation surgery of the genitalia—A pilot study of 47 patients in Sweden. *J Sex Med* 2017; **14**:857-864.
8. Morrison SD, Shakir A, Vyas KS, et al. Phalloplasty: A review of techniques and outcomes. *Plast Reconstr Surg* 2016; **138**:594-615.
9. Morrison SD, Chen ML, Crane CN. An overview of female-to-male gender-confirming surgery. *Nat Rev Urol* 2017; **14**:486-500.
10. Ascha M, Massie JP, Morrison SD, et al. Outcomes of single stage phalloplasty by pedicled anterolateral thigh flap versus radial forearm free flap in gender confirming surgery. *J Urol* 2018; **199**:206-214.
11. Zuckerman JM, Smentkowski K, Gilbert D, et al. Penile prosthesis implantation in patients with a history of total phallic construction. *J Sex Med* 2015; **12**:2485-2491.
12. Hoebeke PB, Decaestecker K, Beysens M, et al. Erectile implants in female-to-male transsexuals: Our experience in 129 patients. *Eur Urol* 2010; **57**:334-340.
13. Krueger M, Haschemi Yekami SA, Hundt GV, et al. Use of erectile prostheses in patients with free forearm flap phalloplasty. *Int J Transgenderism* 2007; **10**:19-22.
14. Solinc M, Kosutic D, Stritar A, et al. Preexpanded radial forearm free flap for one-stage total penile reconstruction in female-to-male transsexuals. *J Reconstr Microsurg* 2009; **25**:395-398.
15. Large MC, Gottlieb LJ, Wille MA, et al. Novel technique for proximal anchoring of penile prostheses in female-to-male transsexual. *Urology* 2009; **74**:419-421.
16. Tan HM. Penile prosthesis implantation in a transsexual neophallus. *Asian J Androl* 2000; **2**:304-306.
17. Hage JJ. Dynaflex prosthesis in total phalloplasty. *Plast Reconstr Surg* 1997; **99**:479-485.
18. Jordan GH, Alter GJ, Gilbert DA, et al. Penile prosthesis implantation in total phalloplasty. *J Urol* 1994; **152**:410-414.
19. Leriche A, Timsit M-O, Morel-Journal N, et al. Long-term outcome of forearm free-flap phalloplasty in the treatment of transsexualism. *BJU Int* 2008; **101**:1297-1300.
20. Zielinski T. Phalloplasty using a lateral groin flap in female-to-male transsexuals. *Acta Chir Plast* 1999; **41**:15-19.
21. Moher D, Liberati A, Tetzlaff J, et al. Preferred reporting items for systematic reviews and meta-analyses: The PRISMA statement. *PLoS Med* 2009; **6**:e1000097.
22. Neuville P, Morel-Journal N, Cabelguenne D, et al. First outcomes of the ZSI 475 FtM, a specific prosthesis designed for phalloplasty. *J Sex Med* 2019; **16**:316-322.
23. Cohen AJ, Bhanvadia RR, Pariser JJ, et al. Novel technique for proximal bone anchoring of penile prosthesis after radial forearm free flap neophallus. *Urology* 2017; **105**:2-5.
24. Khouri RK, Young VL, Casoli VM. Long-term results of total penile reconstruction with a prefabricated lateral arm free flap. *J Urol* 1998; **160**:383-388.
25. Rubino C, Figus A, Dessy LA, et al. Innervated island pedicled anterolateral thigh flap for neo-phallic reconstruction in female-to-male transsexuals. *J Plast Reconstr Aesthet Surg* 2009; **62**:e45-e49.
26. van der Sluis WB, Smit JM, Pigot GLS, et al. Double flap phalloplasty in transgender men: Surgical technique and outcome of pedicled anterolateral thigh flap phalloplasty combined with radial forearm free flap urethral reconstruction. *Microsurgery* 2017; **37**:917-923.
27. Santanelli F, Scuderi N. Neophalloplasty in female-to-male transsexuals with the island tensor fasciae latae flap. *Plast Reconstr Surg* 2000; **105**:1990-1996.
28. Fisch M, Wammack R, Ahlers J, et al. Osseous fixation of a penile prosthesis after transsexual phalloplasty: A case report. *J Urol* 1993; **149**:122-125.
29. Djordjevic ML, Bizic MR, Duisin D, et al. Reversal surgery in regretful male-to-female transsexuals after sex reassignment surgery. *J Sex Med* 2016; **13**:1000-1007.
30. Djordjevic ML, Bencic M, Kojovic V, et al. Musculocutaneous latissimus dorsi flap for phalloplasty in female to male gender affirmation surgery. *World J Urol* 2019; **23**:23.
31. Bettocchi C, Ralph DJ, Pryor JP. Pedicled pubic phalloplasty in females with gender dysphoria. *BJU Int* 2005; **95**:120-124.
32. Djordjevic ML, Bencic M, Kojovic V, et al. Musculocutaneous latissimus dorsi flap for phalloplasty in female to male gender affirmation surgery; *World J Urol*, <https://doi.org/10.1007/s00345-019-02641-w>; E-pub ahead of print.
33. Remington AC, Morrison SD, Massie JP, et al. Outcomes after phalloplasty: Do transgender patients and multiple urethral procedures carry a higher rate of complication? *Plast Reconstr Surg* 2018; **141**:220e-229e.
34. Massie JP, Morrison SD, Wilson SC, et al. Phalloplasty with urethral lengthening: Addition of a vascularized bulbo-spongiosus flap from vaginectomy reduces postoperative urethral complications. *Plast Reconstr Surg* 2017; **140**:551e-558e.
35. Wilson SC, Stranix JT, Khurana K, et al. Fasciocutaneous flap reinforcement of ventral onlay buccal mucosa grafts enables neophallus revision urethroplasty. *Ther Adv Urol* 2016; **8**:331-337.

36. Morrison SD, Perez MG, Nedelman M, et al. Current state of female-to-male gender confirming surgery. *Curr Sex Health Rep* 2015;7:38-48.
37. Morrison SD, Perez MG, Carter CK, et al. Pre- and post-operative care with associated intra-operative techniques for phalloplasty in female-to-male patients. *Urol Nurs* 2015;35:134-138.
38. Morrison SD, Massie JP, Dellon AL. Genital sensibility in the neophallus: Getting a sense of the current literature and techniques. *J Reconstr Microsurg* 2019;35:129-137.
39. Kocjancic E, Iacovelli V. Penile prostheses. *Clin Plast Surg* 2018;45:407-414.
40. Klassen AF, Kaur M, Johnson N, et al. International phase I study protocol to develop a patient-reported outcome measure for adolescents and adults receiving gender-affirming treatments (the GENDER-Q). *BMJ Open* 2018;8:e025435.
41. Massie JP, Morrison SD, Smith JR, et al. Patient-reported outcomes in gender confirming surgery. *Plast Reconstr Surg* 2017;140:236e-237e.
42. Smith JR, Washington AZ 3rd, Morrison SD, et al. Assessing patient satisfaction among transgender individuals seeking medical services. *Ann Plast Surg* 2018;81:725-729.
43. Morrison SD, Dy GW, Chong HJ, et al. Transgender-related education in plastic surgery and urology residency programs. *J Grad Med Educ* 2017;9:178-183.
44. Morrison SD, Chong HJ, Dy GW, et al. Educational exposure to transgender patient care in plastic surgery training. *Plast Reconstr Surg* 2016;138:944-953.
45. Dy GW, Osbun NC, Morrison SD, et al. Exposure to and attitudes regarding transgender education among urology residents. *J Sex Med* 2016;13:1466-1472.